



Physical therapy improves motion in a patient with inclusion body myositis – A case report

Fizikalna terapija poboljšava kretanje kod bolesnika sa miozitisom praćenim inkluzionim telima

¹Jelena Stevanović*, ¹Maja Vulović^{†‡}, Danijela Pavićević[§], Mihailo Bezmarević^{||}, Andjelka Stojković[¶], Aleksandar Radunović^{**}, Miljana Aksić^{††}, Bojan Milošević^{‡‡}, Aleksandar Cvetković^{§§}, Milan Jovanović^{‡§}, Anita Ivošević^{|||}

University of Kragujevac, Faculty of Medical Sciences, *Department of Physical Medicine and Rehabilitation, [†]Department of Anatomy, [¶]Department of Pediatrics, ^{**}Department of Surgery, ^{|||}Department of Internal Medicine, Kragujevac, Serbia; University of Defence, [‡]Faculty of Medicine of the Military Medical Academy, Belgrade, Serbia; Military Medical Academy, ^{||}Clinic for General Surgery, ^{**}Clinic for Orthopedic Surgery, Belgrade, Serbia; University of Kragujevac, ^{††}Faculty of Medical Sciences, Kragujevac, Serbia; Clinical Center Kragujevac, [§]Department of Physical Medicine and Rehabilitation, ^{§§}General and Thoracic Surgery Department, Kragujevac, Serbia

¹Equally contributed first autor

Abstract

Introduction. Inclusion body myositis (IBM) is a rare form of inflammatory myopathy with a slowly progressive course. It is manifested by early weakness and atrophy of skeletal muscles, especially forearm muscles and the quadriceps. At the very beginning of the disease, clinical symptoms are not pronounced, therefore it is difficult to diagnose. **Case report.** A forty-eight-year-old female patient visited her doctor due to the weakness of muscles in arms and legs. Five years prior to this, she was treated by a neurologist and a physiatrist on several occasions with different diagnoses for progressive muscle weakness. During the last hospitalization, IBM was diagnosed after the muscle biopsy findings. After the diagnosis, the patient underwent

intensive physical therapy in order to preserve the ability to independently perform everyday activities and stability of walk. **Conclusion.** IBM is a rare clinical entity which often takes several years to be diagnosed. Progressive muscle weakness in elderly should point to possible IBM diagnosis, which is only confirmed by muscle biopsy. Physical therapy has a significant role in the treatment as it leads to improvement of functional abilities of the patients in their daily activities, thus reducing the disability degree.

Key words: myositis, inclusion body; muscle weakness; physical therapy modalities; biopsy; diagnosis; treatment outcome.

Apstrakt

Uvod. Miozitis sa inkluzionim telima (IBM) je redak oblik inflamatorne miopatije koja ima sporo progresivan tok. Manifestuje se ranom slabošću i atrofijom skeletne muskulature, posebno mišića podlaktice i kvadricepsa. Na samom početku bolesti, klinički simptomi nisu izraženi, pa je postavljanje dijagnoze teško. **Prikaz bolesnika.** Bolesnica stara 48 godina javila se lekaru zbog slabosti u mišićima ruku i nogu. Prethodnih pet godina je u više navrata lečena od strane neurologa i fizijatra sa različitim

dijagnozama progresivne mišićne slabosti. Tokom poslednje hospitalizacije, IBM je dijagnostikovao nakon biopsije mišića. Nakon uspostavljene dijagnoze, bolesnica je prošla intenzivnu fizikalnu terapiju kako bi se očuvala sposobnost samostalnog obavljanja svakodnevnih aktivnosti i stabilnost hoda. **Zaključak.** IBM predstavlja redak klinički entitet kod koga često prođe i više godina do postavljanja dijagnoze. Progresivna slabost mišića kod starijih osoba treba da ukaže na moguću dijagnozu IBM, koja se jedino potvrđuje biopsijom mišića. Fizikalna terapija ima značajnu ulogu u lečenju jer dovodi do poboljšanja funkcionalnih sposobnosti

bolesnica u aktivnostima dnevnog života čime se smanjuje stepen invalidnosti.

Ključne reči:

miozitis sa inkluzionim telima; mišićna slabost; fizikalna terapija; biopsija; dijagnoza; lečenje, ishod.

Introduction

Inclusion body myositis (IBM) is a rare clinical entity which is classified in the group of idiopathic inflammatory myopathies^{1, 2}. It is a complex disorder of an known etiological cause, but genetic, immunological and environmental factors are considered to have significant influence in the development of the disease. Numerous studies have hypothesized that IBM may be an autoimmune inflammatory muscle disorder. The lack of the adequate response to the administration of conventional therapeutic modalities which are used in the treatment of autoimmune diseases points to the role of other factors in the pathogenesis of this disorder^{3, 4}. It is thought that IBM is closely connected to both autoimmune and degenerative processes. Degenerative processes occur in muscle tissue by forming vacuoles, the so called "inclusion bodies", which are the clusters of various unfolded or misfolded proteins. For this reason, it was long believed that IBM was a degenerative disease of muscle tissue⁵. However, recent research has shown that viral infection could be a trigger which induces abnormal response of the immune system and contributes to the development of IBM⁶. Also, some people have genetic predisposition for this disease⁷.

IBM is characterised by chronic, progressive weakness and atrophy of skeletal muscles, especially distal parts of the upper and proximal parts of lower extremities, sometimes followed by the weakness of facial muscles and dysphagia^{2, 8}. Since muscle weakness is the main clinical symptom, the diagnosing of IBM often lasts for a long time due to rare occurrence of the disease. Pathological-histological confirmation of the existence of inclusion bodies in skeletal muscles is the fundamental diagnostic procedure. The lack of adequate pharmacological therapy for the IBM patients together with the progressive course of the disease reduces the performance of everyday activities and leads to disability and restricted movability^{1, 2, 6, 9}.

The aim of this paper is to point to possibilities of occurrence of this disease in the patients with long-lasting muscle weakness, as well as emphasize the necessity of muscle biopsy as a fundamental diagnostic indicator. We also demonstrate the significance of physical therapy as the main treatment of the disease.

Case report

A forty-eight-year-old female patient visited a neurologist at the Clinical Centre in Kragujevac for the first time in 2011 for the weakness in arm and leg muscles, which first appeared eight months before. Electromyography (EMG) and nerve conduction studies (NCS) neurography were done

and showed moderate to moderately strong demyelination polyneuropathy in the lower and upper extremities, which resembled the findings after acute inflammatory demyelination polyneuropathy (AIDP). The physical therapy, electrical therapy and kinesiotherapy were administered, which considerably improved general status; general motor strength (GMS) was also improved so that the patient was significantly more stable while moving.

In 2012 and 2013, the patient was hospitalized at the Clinics of Neurology and Physical Medicine, Clinical Centre Kragujevac twice each year due to the weakness in upper and lower extremities and impaired general condition with various diagnoses: sensorimotor polyneuropathy, status post AIDP and leukoencephalopathy. Each hospitalization at the Rehabilitation Centre lasted for twenty-one days. The treatment was conducted daily, six days per week. Kinesiotherapy programme included the exercises of diaphragm breathing, the exercises for thorax expanding, active exercises for maintaining general mobility, exercises for coordination of movement and when changing from lying to sitting position. Kinesiotherapy was conducted for the duration of 40–45 minutes. During each hospitalization, the functional abilities of the patient were evaluated by the Health Assessment Questionnaire (HAQ). At the first hospitalization, the value of HAQ score was 1, which pointed to slight decrease in functional abilities during everyday activities (moderate disability). Manual muscle test (MMT) was done at each hospitalization and had the values of –4/5 for the upper extremities (UE), and –3/5 for the lower extremities (LE). EMG and NCS showed significant worsening in relation to the ones, done in 2011. Magnetic resonance imaging (MRI) of the brain and cervical and lumbosacral spine showed old three lacunar infarctions in the right parietal lobe. Anosmia was diagnosed during the examination of an allergologist. In addition, ergometric tests were done, showing low probability for cardiovascular diseases; however, it should be noted that the test was not properly done due to the patient's incorrect walk ("leg shuffling"). The analysis of cardiolipin total antibodies (IgG, IgA, IgM) was negative. All laboratory parameters were within limits of reference values. After each hospitalization, rehabilitation treatment was indicated, combined with physical therapy in ambulatory and spa conditions, which led to better and more reliable motions of the patient.

In 2014 and 2015, the patient was hospitalized several times at the Daily Hospital and the Clinic for Neurology, Clinical Centre Kragujevac, with the following diagnoses: paraparesis flaccida, polyneuropathy specifica and Guillain-Barre syndrome. The examination of the cerebrospinal fluid revealed normal fluid composition. Laboratory and serological analyses could not specifically indicate the

existence of Guillain-Barré syndrome, but the clinical picture gave rise to suspicion, and high creatine kinase values indicated the possibility of paraparesis flaccida or polyneuropathy specifica. Hypotrophy of the mimic muscles with light reduction of mimic movements was diagnosed together with a slightly dysarthric speech, reliance on help in changing position from sitting to standing, as well as the hypotrophy of all muscles of upper and lower extremities. The administration of 25 g i.v. of immune globulin IgG-7S did not lead to any improvement. The patient was treated with physical therapy (stable galvanization, electrical stimulation, magnetic therapy, diadynamic currents); kinesiotherapy treatment was conducted in order to reinforce global muscle strength (GMS) and improve walking coordination. HAQ questionnaire was 1, MMT for UE was 3/5, while for LE was 2-3/5. The finding of dual energy X-ray absorptiometry (DEX) of the neck and femur, T-score was -1.1, and regions L1–L4 showed osteopenia.

During the last hospitalization at the Clinic of Neurology (Clinical Centre Kragujevac) in September 2016, muscle biopsy showed IBM. A histological finding showed the presence of muscles of altered architecture with clearly visible necrosis and myofagocytes, due to the presence of inflammatory infiltrates. Inflammatory infiltrate was of the dominant T-lymphocyte type (CD4+, CD8+), with numerous histiocytes and CD8+ lymphocytes invading non-necrotic fibers. Both types of fibers were presented with elements of group atrophy, indicating moderate lesion. In many fibers, the presence of rimmed vacuoles was observed (Figure 1), fibers without cyclooxygenase (COX) activity were present, the expression of the major histocompatibility complex – class I (MHC-I class) of antigens in the inflammation zone, but also in fibers that were not necrotic, was amplified.

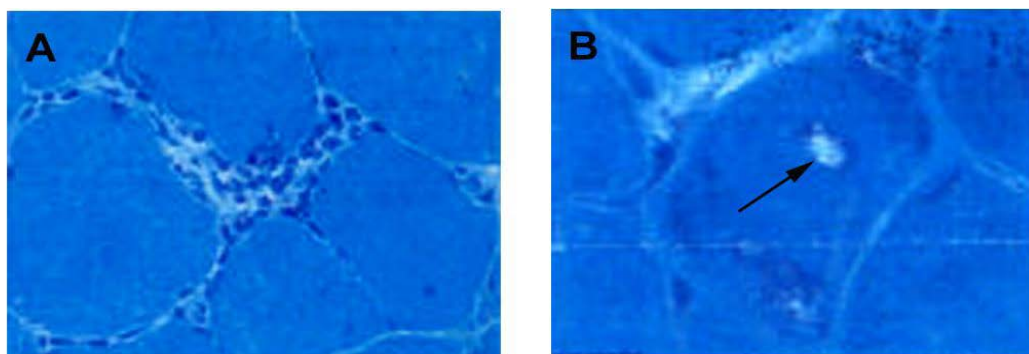


Fig. 1 – Micrography with histological image of the muscle biopsy: A) Myophagocytosis shown on the modified Gomori trichrome staining (10×); B) The presence of a vacuole (arrow), Gomori trichrome staining (40×).

After IBM was diagnosed, the patient was hospitalized at the Centre for Physical Medicine and Rehabilitation, Clinical Centre Kragujevac, where she was administered physical therapy (stable galvanization, transcutaneous electro neural stimulation, diadynamic currents,

kinesiotherapy program) and functional testing. MMT was conducted for UE and LE which showed the values of -3/5 and -2/5, respectively. The value of HAQ questionnaire was 2, which pointed to severe disability (Figure 2).

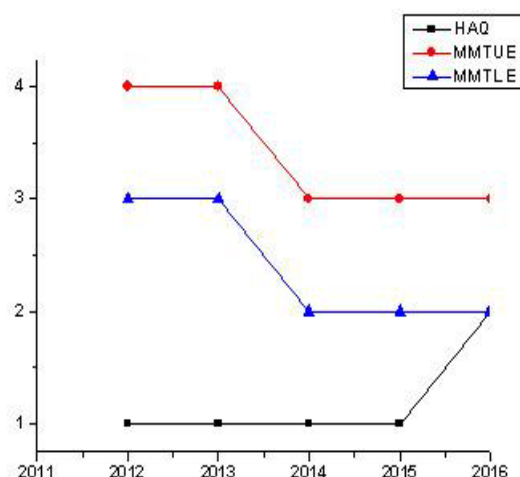


Fig. 2 – The graph shows the effect of physical therapy for a period of 2012–2016 in inclusion body myositis (IBM) measured by Health Assessment Questionnaire (HAQ) and manual muscle testing (MMT). UE – upper extremities; LE – lower extremities.

During the latter hospitalization, the weakness of body flexors and difficulties with motion in bed were noticed together with difficulties in standing up from the chair; however, the patient walked alone on flat surface with the help of a stick with four bottoming points; kinesiotherapy treatment was conducted in patient's room under the supervision of the therapist with daily exchange of tension

and pulsation, since exertion had to be dosed during active exercises. At home, kinesiotherapy included active exercises for general motion and walking on flat surface 2 × 60 minutes, with occasional breaks.

Presentation of the patient's distal parts of upper extremities before and after several cycles of physical therapy is shown in Figure 3.

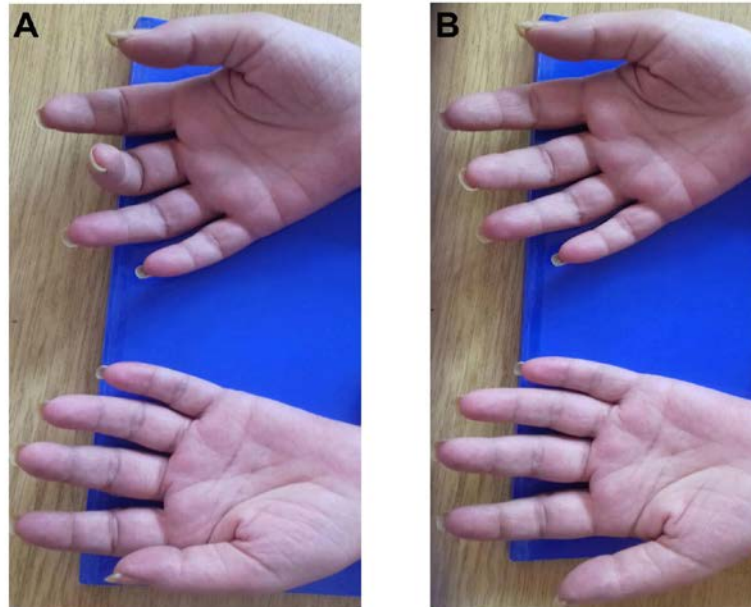


Fig. 3 – Presentation of the patient after the disease was diagnosed: A) Distal parts of upper extremities before physical therapy, and B) after physical therapy.

Discussion

IBM is a rare disease, which more often appears in male in comparison to female population aged over 50, with the ratio 3:1. The frequency of the disease is from 0.001% for those aged less than 50 years to about 0.005% for those aged over 50². Because of such a low frequency and rare occurrence, several years usually pass before the disease is diagnosed, as was the case with our patient³.

IBM is characterized by progressive muscle weakness of distal upper extremities and proximal lower extremities for more than a year in the patients aged over 35, and a normal or moderately increased values of creatine phosphokinase (CPK)². In our patient, muscle weakness was a predominant symptom which worsened overtime. In addition to these symptoms, the patient had diagnoses of anosmia and osteopenia, which have been described in other patients with idiopathic myositis^{10,11}. The crucial parameter to confirm the diagnosis of this disease is a muscle biopsy, which was, in our case, performed 5 years after the onset of muscle weakness^{1,4,7,9}.

Pharmacological therapy has a very small influence on a progressive course of IBM in comparison to other

inflammatory myopathies, thus the patients lose the capacity to perform everyday activities and most often end up in a wheelchair 10–15 years after the onset of the disease^{2,4,9,12–14}. In our patient, administration of immunoglobulins did not lead to any improvement, while the muscle weakness progressed, so the patients could walk only with the help of aids. The aim of physical therapy was to maintain the function and mobility in all joints, thus providing independent mobility as long as possible. At first, the application of physical therapy in IBM was considered contraindicated due to possible increase of inflammatory process in muscles, but later studies pointed to its significance in muscle strength improvement, endurance and increase of functional abilities of the patients related to movement^{1,15}. After the administration of physical therapy in several cycles, general condition of our patient improved. Mobility was made easier and extremity muscles were slightly strengthened. Her walk was more stable, which improved the quality of her life.

Conclusion

IBM is a rare disease which is often diagnosed after many years. Progressive muscle weakness should point to

possible doubt about IBM, which is only confirmed by muscle biopsy. Physical therapy plays a significant role in the treatment of IBM, since it leads to improvement of the functional capacity of patients in daily activities, thus reducing their disability.

Acknowledgement

This study was supported by grant III41020 from the Ministry of Education, Science and Technological Development of the Republic of Serbia.

R E F E R E N C E S

1. *Vattemi G, Mirabella M, Guglielmi V, Lucchini M, Tomelleri G, Ghirardello A*, et al. Muscle biopsy features of idiopathic inflammatory myopathies and differential diagnosis. *Auto Immun Highlights* 2014; 5(3): 77–85.
2. *Dimachkie M, Barohn R*. Inclusion Body Myositis. *Semin Neurol* 2012; 32(3): 237–45.
3. *Garlepp MJ, Mastaglia FL*. Inclusion body myositis: new insights into pathogenesis. *Curr Opin Rheumatol* 2008; 20(6): 662–8.
4. *Dalakas MC*. Sporadic inclusion body myositis – diagnosis, pathogenesis and therapeutic strategies. *Nat Clin Pract Neurol* 2006; 2(8): 437–47.
5. *Needham M, Mastaglia FL*. Sporadic inclusion body myositis: a continuing puzzle. *Neuromuscul Disord* 2008; 18(1): 6–16.
6. *Dalakas MC*. Inflammatory, immune and viral aspects of inclusion-body myositis. *Neurology* 2006; 66(2 Suppl 1): S33–8.
7. *Engel WK, Askanas V*. Inclusion-body myositis. Clinical, diagnostic, and pathologic aspects. *Neurology* 2006; 66(2 Suppl 1): 20–9.
8. *Shams F, Cauchi P*. Lagophthalmos and Ptosis in Inclusion Body Myositis. *Ophthal Plast Reconstr Surg* 2017; 33(3S Suppl 1): S161–2.
9. *Mastaglia FL, Needham M*. Inclusion body myositis: a review of clinical and genetic aspects, diagnostic criteria and therapeutic approaches. *J Clin Neurosci* 2015; 22(1): 6–13.
10. *Iaccarino L, Shoenfeld N, Rampudda M, Zen M, Gatto M, Ghirardello A*, et al. The olfactory function is impaired in patients with idiopathic inflammatory myopathies. *Immunol Res* 2014; 60(2–3): 247–52.
11. *De Andrade DC, de Magalhães Souza SC, de Carvalho JF, Takayama L, Borges CT, Aldrighi JM*, et al. High frequency of osteoporosis and fractures in women with dermatomyositis/polymyositis. *Rheumatol Int* 2012; 32(6): 1549–53.
12. *Alfano LN, Lowes LP, Dvorchik I, Yin H, Maus EG, Flanigan KM*, et al. The 2-min walk test is sufficient for evaluating walking abilities in sporadic inclusion body myositis. *Neuromuscul Disord* 2014; 24(3): 222–6.
13. *Lundberg IE, Vencovsky J, Alexanderson H*. Therapy of myositis: biological and physical. *Curr Opin Rheumatol* 2014; 26(6): 704–11.
14. *Alexanderson H*. Exercise in Inflammatory Myopathies, Including Inclusion Body Myositis. *Curr Rheumatol Rep* 2012; 14(3): 244–51.
15. *Machado PM, Ahmed M, Brady S, Gang Q, Healy E, Morrow JM*, et al. Ongoing developments in sporadic inclusion body myositis. *Curr Rheumatol Rep* 2014; 16(12): 477.

Received on November 10, 2017.

Revised on October 17, 2018.

Accepted on October 17, 2018.

Online First October, 2018.